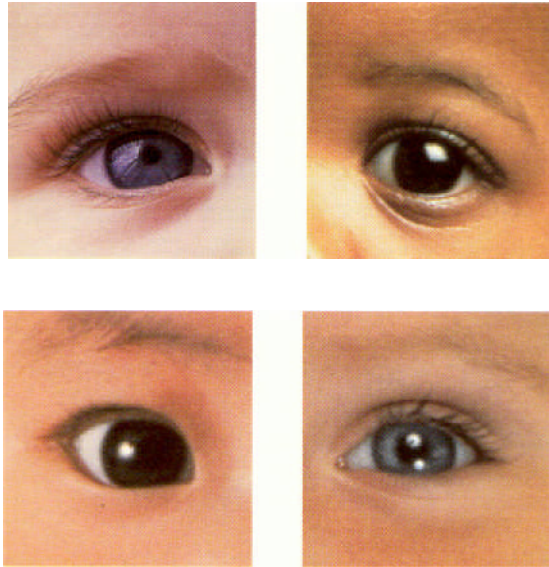


Understanding Retinopathy of Prematurity



WHAT IS RETINOPATHY OF PREMATURITY?

Retinopathy of prematurity (ROP) is an eye disease, which results from abnormal development of the retina (the light-sensitive lining of the eye) in premature babies. Infants are not born with retinopathy of prematurity, They are born with immaturity of the retina (i.e. incomplete development of the retinal blood supply).


Not all premature infants develop retinopathy of prematurity. And for many, it resolves without treatment in early stages. But for those babies in whom ROP progresses, treatment is necessary. ROP generally occurs in both eyes, but may be worse in one eye compared to the other. It is very rare that ROP occurs in only one eye. The two critical factors for predicting which children are most likely to develop ROP are:

- 1, Birth weight of less than 1,500 grams (3 lb 5 oz).
- 2, Gestational age at birth (i.e. length of pregnancy) of less than 32 weeks.

Infants weighing less than 1,000 grams (2 lb 3 oz) at birth and who are born at 23 to 28 weeks gestational age have a particularly high chance of developing retinopathy of prematurity.

Doctors who specialize in the care of newborns (neonatologists) are having increasing success in saving the most premature infants (23 to 24 weeks gestational age) who, just a short time ago, might not have survived - usually because of incomplete development of the lungs. More infants are surviving, and many of them are younger and smaller. A consequence of the increase in survival rate of very premature infants has been an increase in the number of infants at risk for developing ROP as well as in the severity of ROP.

The information in this brochure is intended to help you understand the eye, the disease, and the treatment of ROP.



STRUCTURE AND FUNCTION OF THE EYE

The adult eye is a sphere about 1 inch in diameter. The wall of the eye has three layers:

- Outer fibrous layer — *the sclera*
- Middle vascular layer, containing blood vessels — *the choroid*
- Inner nerve-containing layer — *the retina*

The *cornea* forms the front part of the eye. It is transparent and curved to focus incoming light rays. The *sclera*, commonly called the "white of the eye," forms an opaque and fibrous coat that protects the eye. The *conjunctiva* is an extension of the inner layer on the eyelid that forms a thin transparent membrane over the front of the eye.

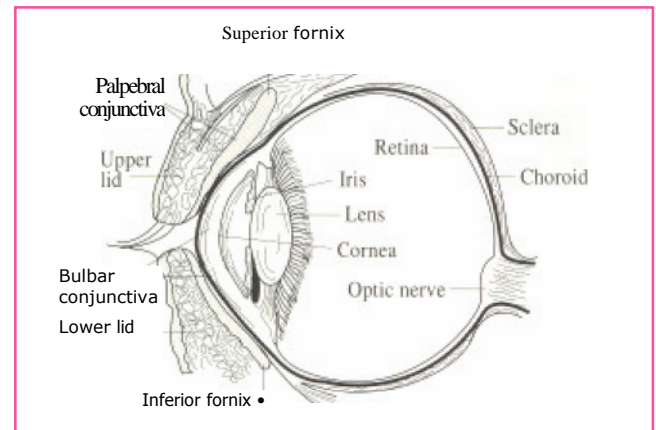



Diagram of the Eye

Many blood vessels and pigment (color) are contained in the choroid. An extension from the front section of the choroid forms the *iris*, or the colored part of the eye. The center of the doughnut-shaped iris is called the *pupil*. Just behind the iris is another extension from the choroid that contains muscles and ligaments that holds the *lens* in place and changes its shape, from squashed for near vision to stretched for far vision.

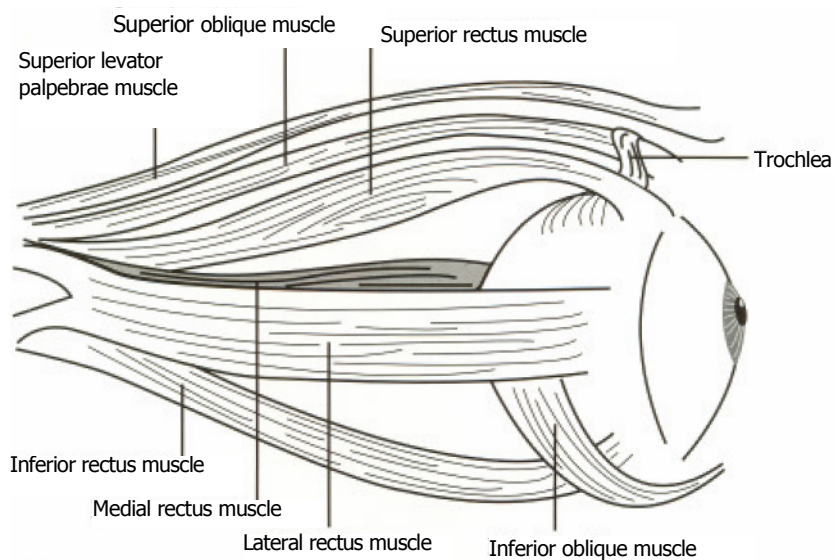
The eye has two segments: The *anterior segment* is from the lens forward, includes the iris and is bound by the cornea at the front. *Aqueous humor*, a watery fluid, constantly flows into and out of the anterior segment. The *posterior segment* lies behind the lens and contains a gelatinous substance called *vitreous humor*. Vitreous humor is formed during the eye's development and, unless removed surgically, remains permanently in the eye. Together, the aqueous and vitreous humor give the eye sufficient pressure, known as *intraocular pressure*, to keep it firm and spherical.

The *retina* forms the inner coat of the posterior segment and is comprised of two layers -- a *nerve-containing layer* resting on top of a *pigmented layer*, which is attached to the underlying choroid. The nerve-containing retina is physically attached to the pigmented retina only at the front of the eye, just behind the lens and at the back of the eye, at the *optic nerve*. When one suffers a detached retina, it is the nerve-containing layer detaching from the pigmented retina, not the entire retina. The nerve layer contains cells - *photoreceptors* - that detect light rays and pass the impulse via the optic nerve, to the brain, which translates them into images. The central part of the retina - *the macula* - is responsible for central vision and is directly behind the lens. At the macula's center is the *fovea*, which is the area of sharpest vision. The retina outside the macula is

known as the *peripheral retina*, which allows peripheral vision.

There are two kinds of photoreceptors in the retina - *rods and cones*. *Rods* are much more sensitive to light and so allow night vision, which is colorless vision and provides only general outlines of objects. *Rods* predominate in the periphery of the retina, but are completely absent from the fovea. *Cones*, on the other hand, detect color and allow sharp vision. The cones are most concentrated in the fovea, but decrease in concentration in areas away from the macula.

The eyeball is held in place in the orbit of the skull by six muscles. Each muscle moves the eye in one primary direction. A given eye movement may involve more than one of the muscles.



Muscles of the Eye

DEVELOPMENT OF THE EYE

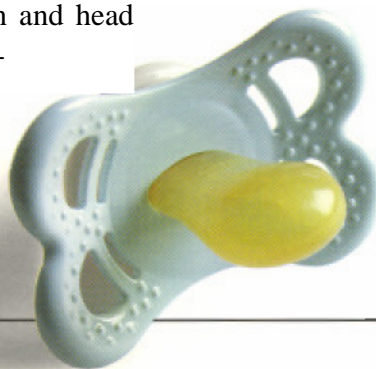
The eye begins to form in the embryo's fourth week of development. The last 12 weeks of a full-term delivery, from 28 to 40 weeks gestation, are particularly active for the growth of the eye of the fetus. At full-term, a baby's eye is almost one half of adult size and continues to develop over the next 2 years.

The anterior segment, or front of the eye, is almost full size at term so most of the continued growth takes place in the posterior segment, just behind the lens in the periphery of the retina. Retinal surface area doubles between 6 months (26 weeks) of gestation and full-term with a further 50% increase over the next 2 years.

The retina (the light-sensitive inner layer of the eye), the iris, and the optic *nerve* (which transmits impulses received by the eye to the brain) all develop from the primitive forebrain. The lens and cornea are derived from the original surface "skin" of the head. (Both help to focus the incoming light rays on the light-sensitive retina.) The embryonic layer between the brain and head gives rise to the vascular (blood vessel-containing) layer, the choroid, and the outer fibrous layer, the sclera.

From about the sixth week of gestation, a temporary network of blood vessels supplies the front of the eye via the *hyaloid artery*, which originates in the back of the eye, passes through the middle of the vitreous humor (the gelatin that fills the back segment of the eye) and wraps vessels around both surfaces of the lens and iris. The hyaloid artery later incorporates into the optic nerve behind the eye and disappears from inside the eye by 7 months of gestation. The vessels around the lens usually disappear by 34 weeks' gestation.

There are no blood vessels in the retina before the sixteenth week of gestation. From then on, primitive cells extend out from the *optic disc* (where the optic nerve enters the eye) and stimulate the growth of normal blood vessels. Production of the new blood vessels is usually complete on the nasal side (towards the nose) of the eye by 8 months (35 weeks) gestation. The blood vessel networks on the temporal side of the eye (towards the side of the head or temples) are not mature until 2 to 3 months after normal term birth.



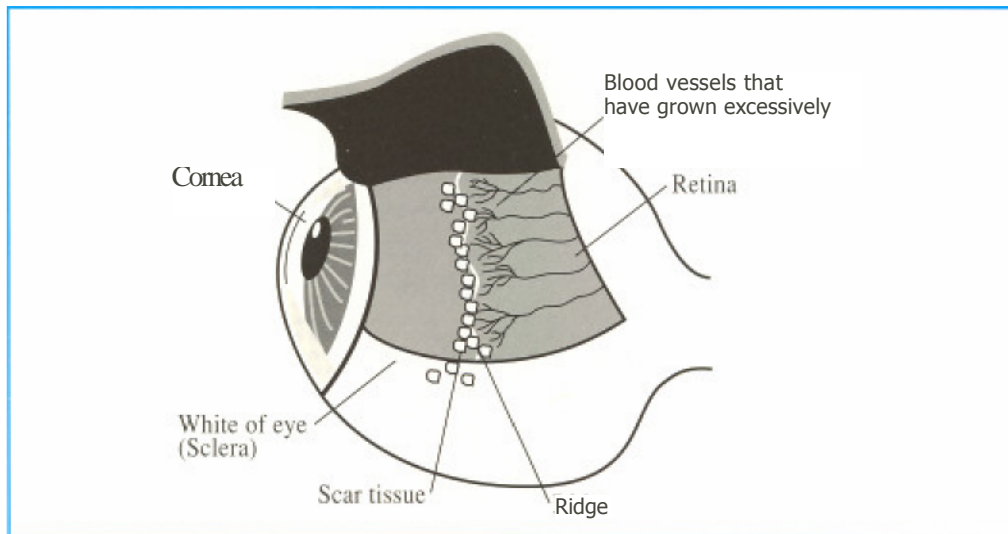
DEVELOPMENT OF ROP

As discussed earlier, growth of the blood supply to the retina begins at 16 weeks of gestation and proceeds until a little after a full-term birth. If the retinal blood supply in the premature infant continues its development just as if the baby were still in the uterus, then retinopathy of prematurity does not develop.

ROP occurs when abnormal blood vessels and scar tissue form at the edge of the normal retinal blood supply. If retinopathy of prematurity develops, it usually appears between 35 and 45 weeks of conceptive age. That is if the infant is born at 30 weeks gestation, and if retinopathy of

prematurity were to occur, it would appear when the infant is between 5 and 15 weeks old. In the majority of infants who develop ROP, the disease resolves spontaneously and the retinal blood supply develops normally. If retinopathy of prematurity regresses, the disease has usually lasted about 15 weeks.

However, ROP can progress to a serious, and potentially blinding, *eye* problem, which is estimated to result in the blindness of approximately 500 infants in the United States per year.



A premature eye with retinopathy of prematurity

CLASSIFICATION OF ROP

In the 1980's, an international standard classification of retinopathy of prematurity (known as ICROP) was developed by a team of 23 experts from around the world. It defines the disease by location relative to the optic nerve and macula, by extent of disease around the circumference of the eye, and by stages of progressive disease.

Location

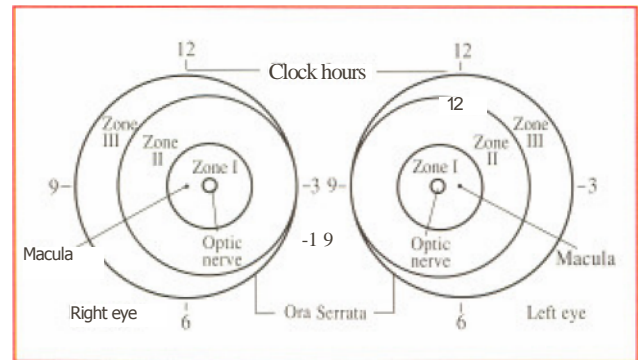
Blood vessel development *in* the retina occurs from the optic nerve out towards the periphery, that is, from the back of the eye towards the front. The location of the disease is referred to by the ICROP classification and is a measure of how far this normal progression of blood vessel development has progressed before the disease takes over. Generally Zone II disease is more severe than Zone III disease, and Zone I disease is the most dangerous of all since progression to extensive scar tissue formation and total retinal detachment is most likely in this location.

From the "flattened" retina in the diagram to the right you can see that:

- **Zone I** is a small area around the optic nerve and macula at the very back of the eye.
- **Zone II** extends from the edge of Zone I to

the front of the retina on the nasal side of the eye (i.e. nose side) and part way to the front of the retina on the temporal side of the eye (i.e. temple side, or side of the head).

- **Zone III** is the remaining crescent of retina in front of Zone II on the temporal side of the eye.



Scheme of retina of right eye (RE) and left eye (LE) showing zone borders and clock hours employed to describe location and extent of retinopathy of prematurity.

Extent of Disease

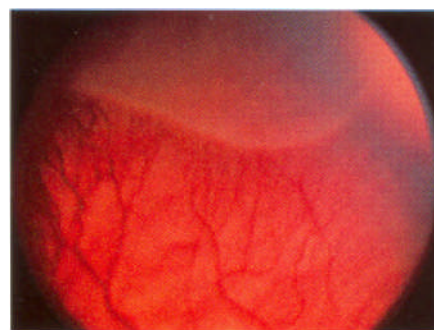
Think of the eye as in time sections of a twelve-hour clock. The extent of ROP is defined by how many clock hours of the eye's circumference is diseased. The numbers around the "flattened" retina in the diagram show the hours

of the clock for each eye. For example, 3 o'clock is to the right, which is on the nasal side for the right eye and temporal side for the left eye. Often the disease is not present around all twelve clock hours, so a description may often refer to "x" number of clock hours of disease (e.g. nine clock hours would mean that three-quarters of the circumference of the retina is involved).

Stages of the Disease

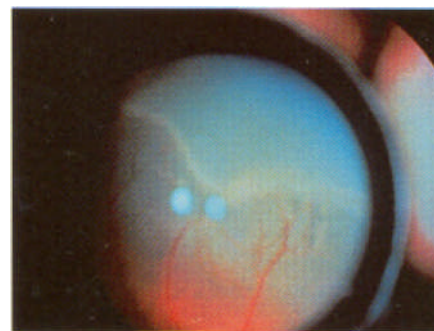
Retinopathy of prematurity is a progressive disease. It starts slowly, usually anywhere from the fourth to the tenth week of life, and may progress very fast or very slowly through successive stages, from Stage 1 through Stage 5. Or it may stop at Stage 1, Stage 2, or mild Stage 3 and disappear completely.

Stage 1 ROP is characterized by a demarcation line separating the clearly normal retina from the undeveloped retina. This line is typically white and there is sharp contrast between the normal retina and the abnormal retina.



*Stage 1 Retinopathy of Prematurity**

Stage 2 ROP displays a rolled ridge of scar tissue in place of the white demarcation line of Stage 1. It may be limited to a small area of the retina or it may encircle the entire inside of the eye like a belt around the middle of the eye.

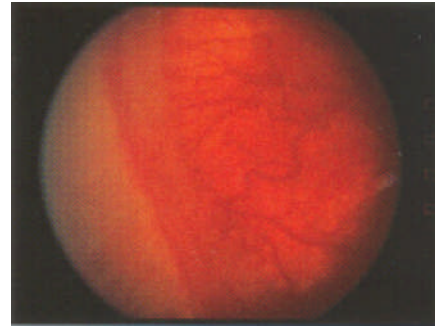


Stage 2 Retinopathy of Prematurity

*Reprinted with permission from Palmer Earl A., MD: "The Multicenter Trial of Cryotherapy for Retinopathy of Prematurity" in *Focal Points: Clinical Modules for Ophthalmologists*. (Vol II, Module 12), American Academy of Ophthalmologists, San Francisco, 1984

Stage 3 ROP is characterized by the development of abnormal "new blood vessels" and fibrous tissue (like scar tissue) on the edge of the ridge seen in Stage 2 and extending into the vitreous (the back cavity of the eye). Stage 3 is further divided into:

- "Mild" — with only a limited amount of abnormal tissue,
- "Moderate" — with significant amounts of abnormal tissue infiltrating into the vitreous, or
- "Severe" — massive amounts of abnormal tissue infiltrate into the vitreous.

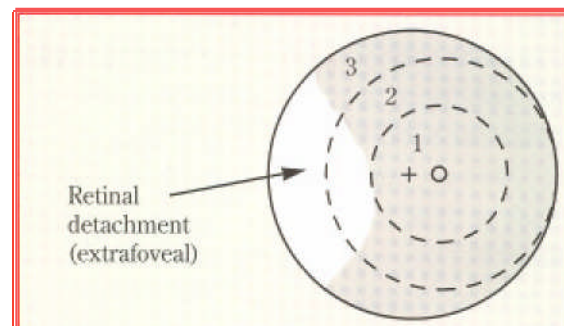


Severe Stage 3 Retinopathy of Prematurity

Statistically, eyes which reach Stage 3 disease have a 50% chance of proceeding to Stage 4 or Stage 5 and possible blindness; therefore, it is at Stage 3 that treatment is instituted.

Stage 4 ROP is caused by scar tissue pulling on the retina and causing it to separate from the wall of the eyeball. The detachment in Stage 4 is partial, occurring in one section of the eye, and depending on its location, may or may not affect the infant's vision. Stage 4 is further categorized depending on the location of the partial detachment:

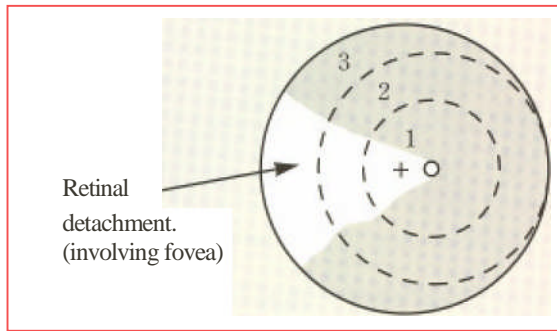
- Stage 4A is a partial detachment outside the macula — the area of central vision — in the



Stage 4A Retinopathy of Prematurity

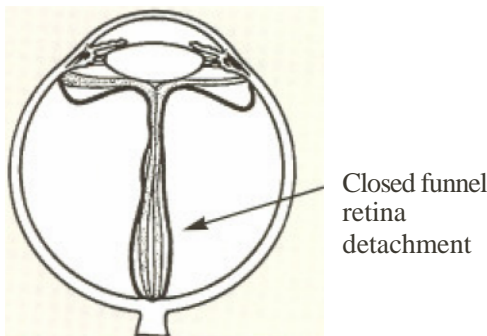
periphery of the retina; therefore, the chance for usable vision, if the retina reattaches, is relatively good.

- Stage 4B is partial detachment involving the macula, usually with a fold extending out through Zones I, II, and III. The involvement of the macula severely limits the prospect for usable vision in this eye.



Stage 4B Retinopathy of Prematurity

Stage 5 ROP involves a complete retinal detachment, with the retina assuming a closed or partially closed funnel, from the optic nerve to the front of the posterior cavity of the eye, just behind the lens.



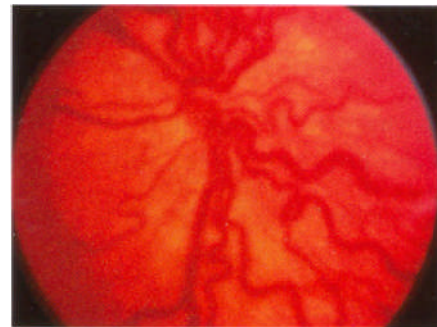
Severe Stage 5 Retinopathy of Prematurity

Infants with Stage 5 ROP have essentially no useful vision in that eye. Treatment at this stage involves surgery to relieve the traction, causing the detachment, in an attempt to reattach the retina. Some vision may be recovered by this surgery, but the infant will most likely be legally blind in the involved eye.

Plus Disease

Additional changes to those described in Stages 1 through 5 may involve abnormal blood vessels in the iris and engorgement and tortuosity (i.e. repeated twists, bends or turns) of the normal blood vessels in the retina. If these additional symptoms are particularly bad, the plus ("+") designation is added to the Stage number, e.g. Stage 2+.

If ROP is located in Zone 1 and there is plus disease present, then progression of the disease may be particularly rapid. This form is sometimes called Rush Disease.



Plus Disease

DIAGNOSIS OF ROP

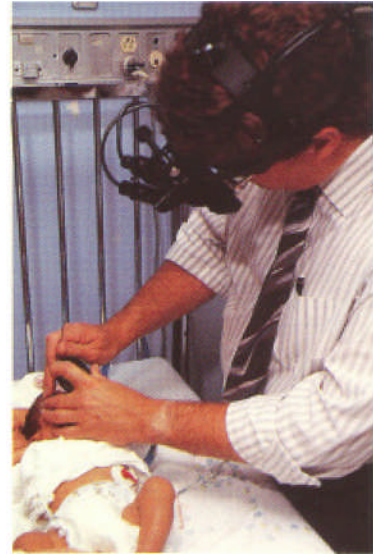Screening for ROP usually begins when the infant is about 4 to 6 weeks of age. An ophthalmologist, who specializes in either retinal disorders (retinal specialist) or children's eye diseases (pediatric ophthalmologist), uses a special instrument (an indirect ophthalmoscope) which allows a view through its optic lens into the back of the eye to examine the retina and determine whether development of the blood vessels is occurring normally or not.

The infant is usually given some eye drops to make the pupils dilate so that the viewing field is as wide as possible. A light anesthetic, in the form of numbing eye drops, may also be administered.

The examinations are usually performed in the neonatal intensive care nursery where the neonatal staff can continue to monitor the baby.

The infant will continue to be examined every 1 to 2 weeks until one of the following occurs:

- Development of the normal blood supply to the retina is complete.
- Two successive 2-week exams show Stage 2 ROP in Zone III. Infants will then be examined every 4 to 6 weeks until the blood supply to the retina is fully developed.



A physician doing an indirect ophthalmoscope exam

- ROP is at "prethreshold," just prior to requiring treatment. Follow-up exams will then occur every week until either Threshold ROP occurs (i.e. the point at which a physiological effect begins) which requires treatment, or the retinopathy of prematurity disappears.
- The ROP is disappearing.

After two successive 2-week exams have shown regression, examinations should be continued every 4 to 6 weeks.

Once the normal blood supply to the retina is completely developed, the infant will continue to be examined every 6 to 12 months by a pediatric ophthalmologist or retinal specialist to ensure that no further complications of ROP occur.

TREATMENT OF ROP

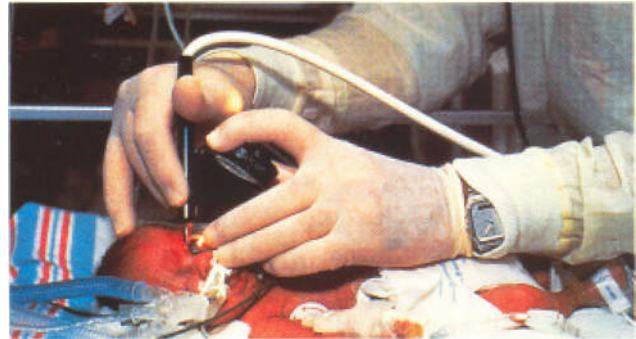
Cryotherapy

In the late 1980's, a nationally-organized clinical trial established that cryotherapy, a freezing process, improved the outcome of the disease for infants who had reached Threshold Stage 3+ in 50% of cases. That is, half of the treated eyes that would otherwise (i.e. without treatment) have progressed to retinal detachment and possible blindness, did not do so,

The technique of cryotherapy involves freezing the retina by touching a cold probe to the outside of the eye and waiting to allow the freeze to reach the abnormal retina (i.e. the retina without a blood supply) inside the eye. The treatment kills the abnormal retina, the abnormal blood vessels disappear, and the progression of scar tissue stops.

There are risks in performing cryotherapy. Severe decreases in heart rate and breathing rate may occur. For this reason, heart rate and blood oxygen are monitored constantly during the cryotherapy procedure. Sometimes infants need to be placed back on a ventilator after the procedure if they are having trouble breathing on their own.


Cryotherapy is performed under local anesthesia or general anesthesia. If local anesthesia is



Cryotherapy Treatment

used, it can be administered and the procedure performed at the infant's bedside in the neonatal intensive care nursery. Administration of general anesthesia may require that the infant is transferred to the operating room. Neonatal staff also accompanies the baby to ensure constant monitoring of his or her condition. Some physicians prefer to give general anesthesia because they believe that cryotherapy is such a painful procedure, that it is in the infant's best interest to be fully anesthetized.

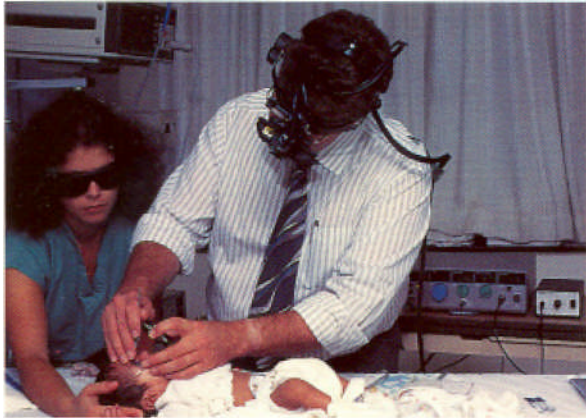After cryotherapy, there is usually a large amount of swelling around the eyes, bloody tears, and redness. These effects go away in approximately 1 week.



Lasers

An alternative to cryotherapy is laser therapy. Laser therapy may achieve the same effects as cryotherapy with fewer side-effects and is now considered the primary treatment for ROP.

Lasers have been used to successfully treat eye disorders in adults for over 20 years. Diabetic retinopathy is a retinal disease afflicting diabetics, which like retinopathy of prematurity involves growth of abnormal blood vessels in the retina. Treatment of diabetic retinopathy was revolutionized by the advent of laser therapy. Prior to laser therapy, there was no way to prevent blindness in these people.



Laser Treatment

Due to a technical advance in the last few years, laser therapy can now be administered to newborn infants. The indirect ophthalmoscope, that the doctor uses to examine the infant's retina, can also be used with an attachment that can deliver laser treatment to the eye.

Laser treatment acts in the same way as cryotherapy by killing the abnormal retinal tissue and so eliminates the growth of abnormal blood vessels and ends the progression of scar tissue formation.

The potential benefits of laser treatment are:

- Less need for anesthesia
- Less pain
- Less swelling after the procedure
- Less likelihood of damage to the eye
- Less chance of decrease in heart and breathing rates during the treatment

Traditional laser systems were large, immobile units that required moving the infant to the laser rather than bringing the laser to the baby. Newer lasers — using semiconductors — are fully portable and can be taken to the nursery and attached to an indirect ophthalmoscope for treating babies with ROP without disturbing their routine. Studies indicate that laser therapy is at least as effective as cryotherapy and potentially better at preventing many infants from progressing to retinal detachment.

As mentioned earlier, advances in infant care have helped more premature infants survive. Many of these infants are very premature, and their eyes accordingly very immature. This has resulted in an increase in Zone 1 ROP, which presents a particular challenge to eye doctors (ophthalmologists), as the traditional mainstay of therapy for ROP — cryotherapy appears to not be as effective for threshold ROP in Zone 1

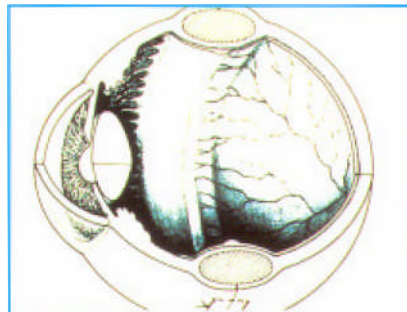
eyes. Data from several studies suggest that laser may be particularly useful in treating these high risk eyes. If cryotherapy or laser treatment at Stage 3 is unsuccessful in preventing progression to retinal detachment stages (Stage 4 and Stage 5), there are surgical treatment options.

Surgery

A surgical technique called *scleral buckling* may be effective to treat retinal detachments, especially if the detachment is shallow (i.e. there is not a lot of space between the retina and the eye wall). Scleral buckling involves placing a belt around the outside of the eye and tightening it until the retina is close enough to the wall to reattach itself. Studies have shown this technique to be effective in some cases of Stage 4a, Stage 4b, and mild Stage 5. Vision after successful scleral buckling tends to be better than after the more invasive surgical procedures discussed below. These procedures are generally performed on more serious retinal detachments.

If scleral buckling is not possible or is unsuccessful, a more direct technique for reattaching the retina, called a *vitrectomy*, can be performed.

In some vitrectomy procedures, the eye is opened up, the lens is removed and some or all of the vitreous humor is removed so the surgeon can access the detached retina. The source of traction causing the detachment (i.e. the scar tissue or membrane that is tugging at the retina) is cut away from the retina and the retina is then laid back against the eye wall. Sometimes




Scleral Buckling

a gelatin-like material is injected to replace the vitreous that was removed.

An alternative procedure to the lens removal technique that may provide better and quicker optical recovery, is a technique called *lens-sparing vitrectomy*. A lens-sparing vitrectomy involves two instruments shaped like hypodermic needles that are inserted through the eye (outside of the iris, keeping the lens intact) into the vitreous cavity. These instruments are used to remove the scar tissue and to perform a fluid-gas exchange. As the fluid is removed through one instrument, gas or air is injected into the vitreous cavity through the other instrument.

There is some evidence that eyes with severe retinal detachments treated with vitrectomy function somewhat better than eyes without vitrectomy; however, vitrectomies are not always successful in reattaching the retina. Even if the retina is reattached, only a fraction of eyes achieve the ability to recognize faces.



LATE COMPLICATIONS OF ROP

Most infants with mild retinopathy of prematurity (Stages 1 to mild Stage 3) that spontaneously resolves itself will have no remaining scar tissue. However, some infants who undergo regression may still suffer further complications later in life. These later complications include:

Strabismus and Amblyopia

Strabismus (crossed eyes) and *amblyopia* (lazy vision in one eye) occur more frequently in infants with even the mildest stages of regressed ROP compared with premature infants who do not develop ROP. Eye muscle surgery (for strabismus) and patching (for amblyopia) are often necessary.

Myopia

Myopia (near-sightedness) can occur with the mildest forms of regressed ROE. The near-sightedness is usually more severe when a greater amount of scar tissue remains from regressed ROP. Myopia is correctable with glasses.

Glaucoma

Different forms of *glaucoma* (increased pressure in the eye) may develop in eyes that have regressed or treated ROP. Glaucoma may cause pain and does damage vision. Laser, or other

types of surgery, is sometimes necessary to help the eye drain off the build-up of the watery fluid (aqueous humor) that causes the increased pressure.

Late-onset Retinal Detachment

Late retinal detachment may rarely occur in the mid-teens or early adulthood as a result of traction from scar tissue as the eye grows or as the vitreous gel shrinks, pulling holes in the retina. Surgery is usually necessary for repair. Therefore, any person who experienced retinopathy of prematurity should see a retinal specialist and/or a pediatric ophthalmologist at least once a year during childhood and early adult years.



References

- Capone A, Diaz-Rohena IC, Sternberg Mandell BA, Lambert I-IM, Lopez PE, Aaberg TM. Indirect Diode Laser Photocoagulation in the Management of Threshold Zone 1 Retinopathy of Prematurity (Rush Disease). *American Journal of Ophthalmology*. 1993. Volume 116, pp 444-450.
- Committee for the Classification of Retinopathy of Prematurity. An International Classification of Retinopathy of Prematurity. *Archives of Ophthalmology*, 1981. Volume 102, pp 1131-1134.
- Cryotherapy for Retinopathy of Prematurity Cooperative Group, Multicenter Trial of Cryotherapy for Retinopathy of Prematurity: One Year Outcome Structure and Function. *Archives of Ophthalmology*. 1990. Volume 108, pp 1408-1418.
- Cryotherapy for Retinopathy of Prematurity Cooperative Group, Multicenter Trial of Cryotherapy for Retinopathy of Prematurity: Preliminary Results. *Archives of Ophthalmology*. 1988, Volume 106, pp 471-479.
- Cryotherapy for Retinopathy of Prematurity Cooperative Group. Multicenter Trial of Cryotherapy for Retinopathy of Prematurity: Three Month Outcome. *Archives of Ophthalmology*, 1990. Volume 108. pp 195-204.
- de Juan Jr. E, Machemer R. Retinopathy of Prematurity - Surgical Technique. *Retina*, April-June 1987. Volume 7.
- Fielder AR, Moseley HJ, Ng YK. The Immature Visual System and Premature Birth. *British Medical Bulletin*, 1988. Volume 44. pp 1093-1118.
- Fleming TN, Runge PE, Charles ST. Diode Laser Photocoagulation for Pre-threshold, Posterior Retinopathy of Prematurity. *American Journal of Ophthalmology*, 1992. Volume 114, pp 589-592.
- Flynn JT, Phelps DL. Retinopathy of Prematurity: Problem and Challenge. *Birth Defects: Original Article Series*. 1988, Volume 24, no 1. Alan R. Liss, Inc. Publishers.
- Flynn JT, Bancalari E, Bachynski BN, et al. Retinopathy of Prematurity: Diagnosis, Severity and Natural History. *Ophthalmology*, 1987. Volume 94, pp 620-629.
- Gaynon MW. Retinopathy of Prematurity, *Pediatrician*, 1990. Volume 17, pp 127-133.
- Goggin M, O'Keefe M. Diode Laser for Retinopathy of Prematurity - Early Outcome. *British Journal of Ophthalmology*, 1993. Volume 77, pp 559-582.
- Hole Jr. JW. *Human Anatomy and Physiology*. 2nd Edition. 1981. William C. Brown Company Publishers.
- International Committee for the Classification of the Late Stages of Retinopathy of Prematurity. An International Classification of Retinopathy of Prematurity, II: The Classification of Retinal Detachment. *Archives of Ophthalmology*, 1987. Volume 105, pp 906-912.
- Landers III MB, Sempke HC, Ruben JR, Serdahl C. Argon Laser Photocoagulation for Advanced Retinopathy of Prematurity. *American Journal of Ophthalmology*, 1990- Volume. 110, pp 429-431.
- Maguire AM, Tense MT. Lens-Sparing Vitreoretinal Surgery in Infants. *Archives of Ophthalmology*, 1992. Volume 110. pp 284-286.
- McNamara JA, Tasman WS, Brown GC, Federman JL. Laser Photocoagulation for Stage 3+ Retinopathy of Prematurity. *Ophthalmology*, 1991. Volume: 98, pp 576-580.
- McNamara JA, Tasman WS. Retinopathy of Prematurity. *Ophthalmology Clinics of North America*, 1990. Volume 3, pp 413-427.
- Parker AC, Thibodeau GA. *Textbook of Anatomy and Physiology*. 11th Edition, 1983. The C.V. Mosby Company.
- Seater JG, Machenter R, Elliott D, Buckley EC, de Juan E, Martin DE. Long-term Visual Results of Children After Initially Successful Vitrectomy for Stage V Retinopathy of Prematurity. *Ophthalmology*, 1995, Volume 102, pp 199-204.
- Seiberth Linderkamp O, Vardarli I, Knorz M, Liesenhoff H. Diode Laser Photocoagulation for Stage 3+ Retinopathy of Prematurity. *Graefes Archives of Clinical Experimental Ophthalmology*, 1995. Volume 233, pp 489-493.
-

GLOSSARY OF TERMS

Amblyopia - Lazy vision in one eye

Anterior Segment - Front section of the eye, including the lens

Aqueous Humor - Fluid produced in the eye, occupying the anterior and posterior chambers

Choroid - Middle layer of the eye containing blood vessels

Cones - Nerve cells in the retina responsible for sharp vision and detection of color

Conjunctiva - Thin membrane covering the front of the eye

Cornea - Front transparent part of the eye

Cryotherapy - Freezing treatment to kill abnormal retina

Embryo - A developing baby up to 12 weeks after conception

Fetus - A developing baby from 12 weeks' gestation to birth

Fovea - Center of the macula responsible for the sharpest vision

Gestation - How long the pregnancy has lasted

Glaucoma - increased pressure in the eye, which is potentially blinding if not lowered

Hyaloid Artery - Artery that supplies blood to the front of the eye during development of the embryo/fetus

Indirect Ophthalmoscope - instrument used to look through the lens of the eye and into the back of the eye

Intraocular Pressure -The pressure inside the eye

Iris - Colored part of the eye, doughnut shaped

Laser - Powerful beam of light that is used to kill abnormal retina

Lens - Football-shaped structure behind the pupil that bends the incoming light rays and focuses them onto the retina

Lens-Sparing Vitrectomy - Surgical procedure for reattaching the retina, keeping the lens intact

Macula - Part of the retina directly behind the lens, which is responsible for central vision

Myopia - Near-sightedness

Nasal Side - Closest to the nose

Optic Disc - Area where the optic nerve exits at the back of the eye

Optic Nerve - Carries impulses received by the retina to the brain for interpretation of images

Peripheral Retina - Part of the retina closest to the front of the eye

Plus Disease - When normal blood vessels become abnormally twisted and bloated, can occur at any stage of retinopathy of prematurity

Posterior Segment - Back section of the eye, behind the lens

Pupil - Black hole in the center of the iris

Retina - Inner light-sensitive layer of the eye

Retinal Detachment - Part or all of the light-sensitive retina comes away from the wall of the eye

Rods - Nerve cells in the retina that detect general shapes of objects and are responsible for colorless vision and night vision

Rush Disease - An aggressive form of retinopathy of prematurity that progresses rapidly

Sclera - Outer layer of the eye, the "white of the eye"

Scleral Buckle A "belt" that goes around the eye to prevent or treat small areas of retinal detachment

Strabismus - Crossed eyes

Temporal - Closest to the temples, or the side of the head

Uterus - Womb

Vitrectomy - Surgical procedure for reattaching the retina

Vitreous Humor - Gelatinous material that fills the cavity in the back of the eye and gives the eye shape

NOTES





IRIS Medical. *Education*

© 1992, 1996 IRIS Medical Instruments, Inc., a subsidiary of IRIDEX Corporation
340 Pioneer Way Mountain View, CA 94041
Phone: 1-800-388-4747 (U.S.) 415-962-8100 (Int'l) FAX: **415-962-0486**

